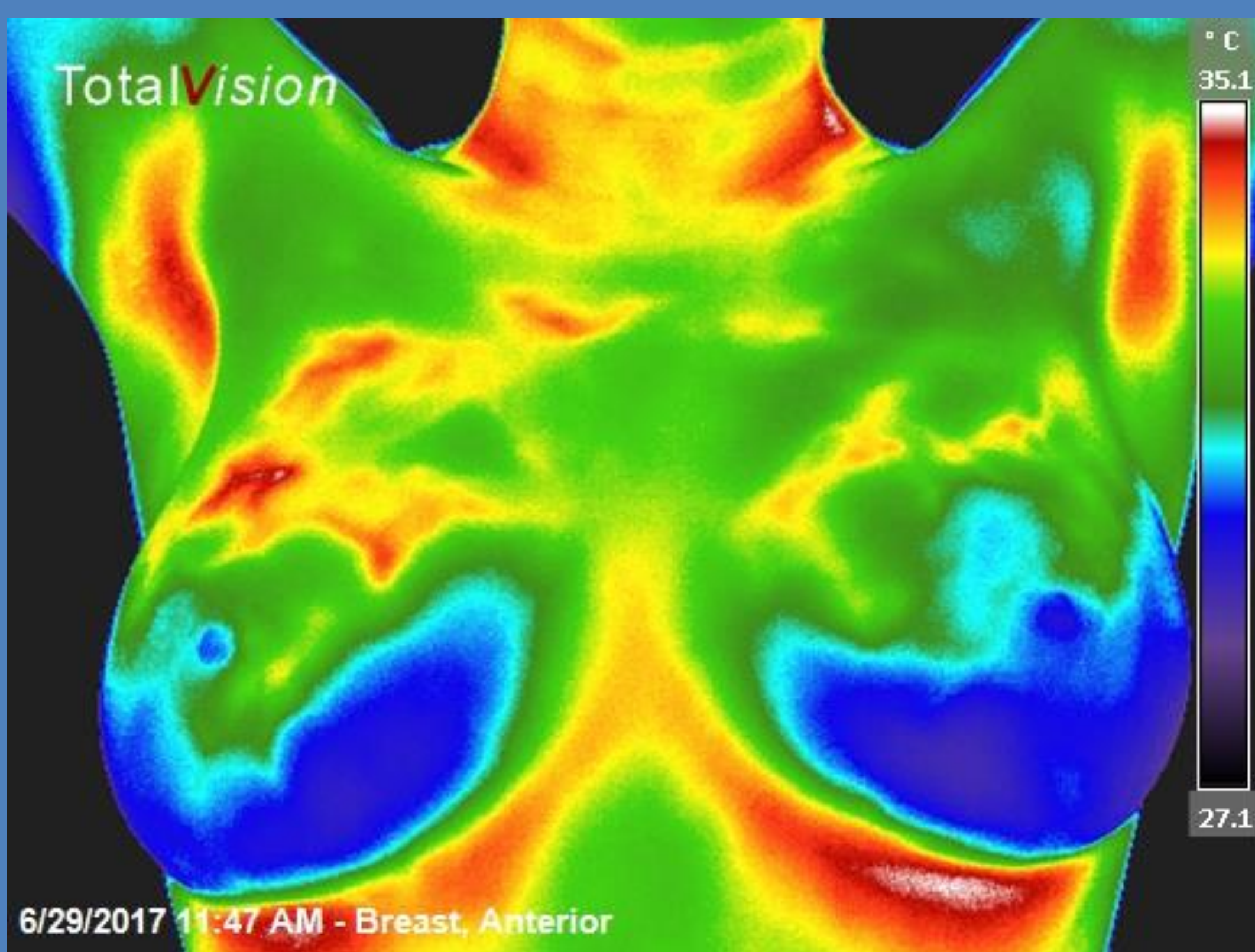
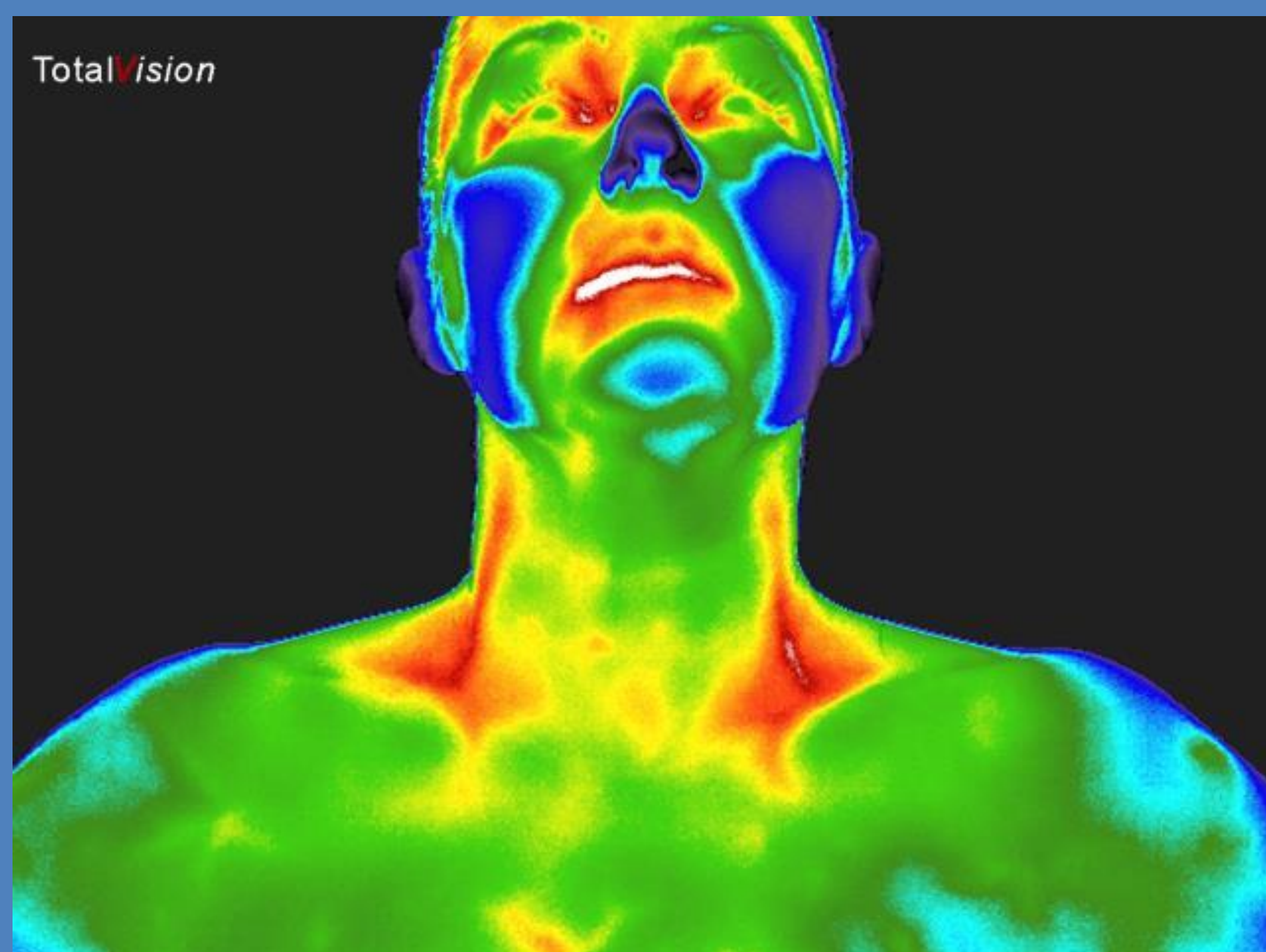
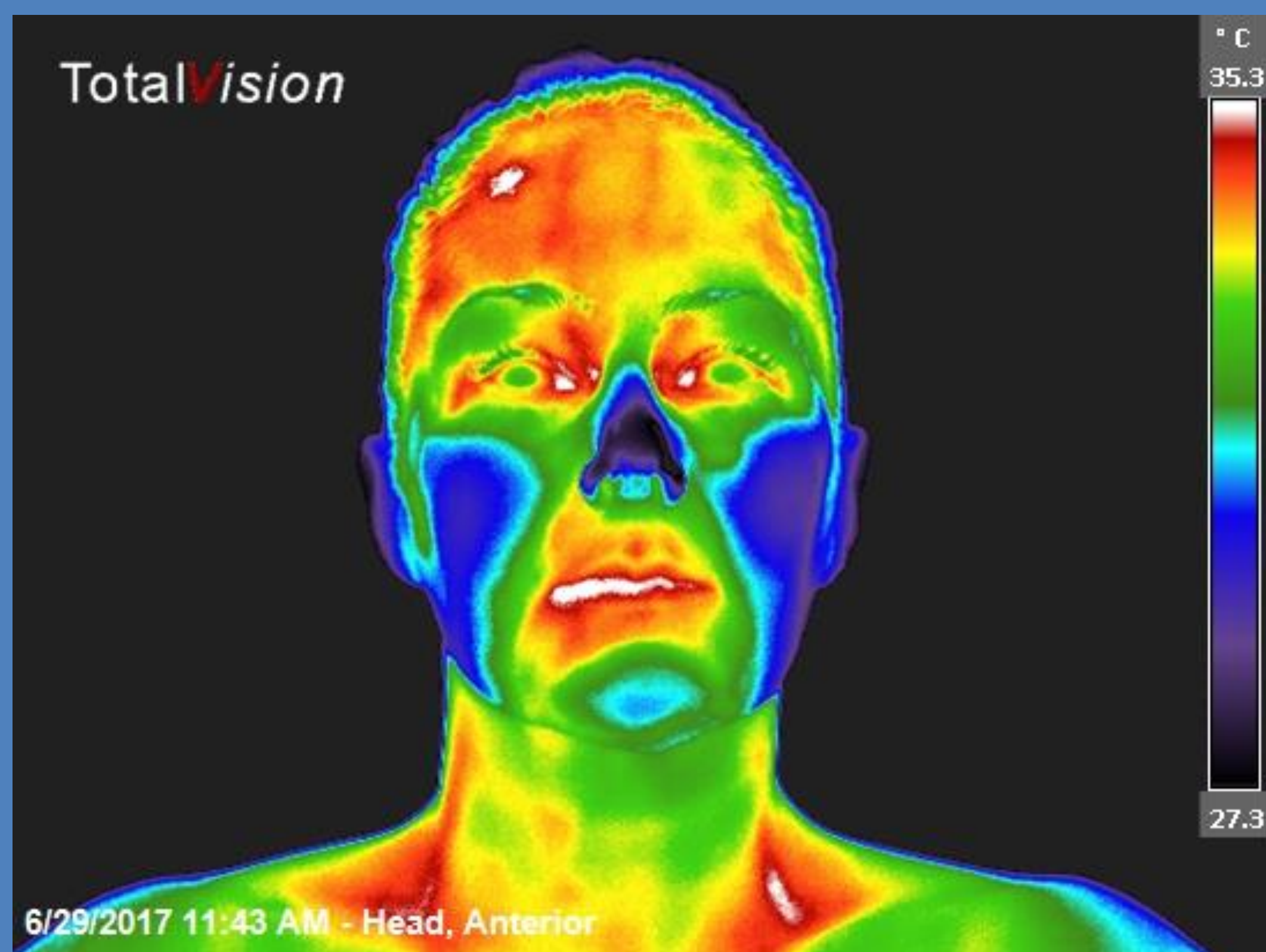
MONITORING TOOL

Path of Dental Inflammation: Before & After

Nicole Benson, CTT
Thermography Medical Clinic

BEFORE
06/29/2017



Introduction

Thermography can be used to identify not only dental concerns, but also the path of bacteria and inflammation stemming from teeth to other areas of the body. Studies show there is a relationship between oral health and 90% of all systemic diseases in the body.

Patient: F - 33yrs old

The patient came to the clinic with complaints of severe chronic headaches. She also has family history of breast cancer. Patient reported right wisdom tooth needed removal & root canal needed to be done on the right side of mouth.

June Findings & Discussion

Significant thermal asymmetry in the head, neck, and breast. Inflammation on the right side of the mouth, right side of the head, right side of thyroid and into the right breast. Thermographer suspected bacteria from the unresolved dental issues was causing the path of inflammation up the head, and down through the thyroid into the breast.

January Follow Up

The client had her right wisdom tooth removed in October 2017, and had a root canal upper right in December 2017. The follow up shows significant decrease of inflammation in the right side of the mouth, head, thyroid, axillary lymph nodes, and breast.

AFTER
01/08/2018

