

Lena Azevedo, CTT

Thermography Medical Clinic and D'Vine Living

### Introduction

Endometriosis is a widely encountered but poorly understood condition (as is the case with most hormonal disorders). It affects, by some estimates, up to 20 percent of women of reproductive age – millions of women.

Inflammation and hormonal balance play key roles in the genesis and pain generation within endometriosis.

In our experience, Thermography is a valuable Discovery Tool to assist in the detection, assessment and monitoring of some of leading causes of endometriosis.

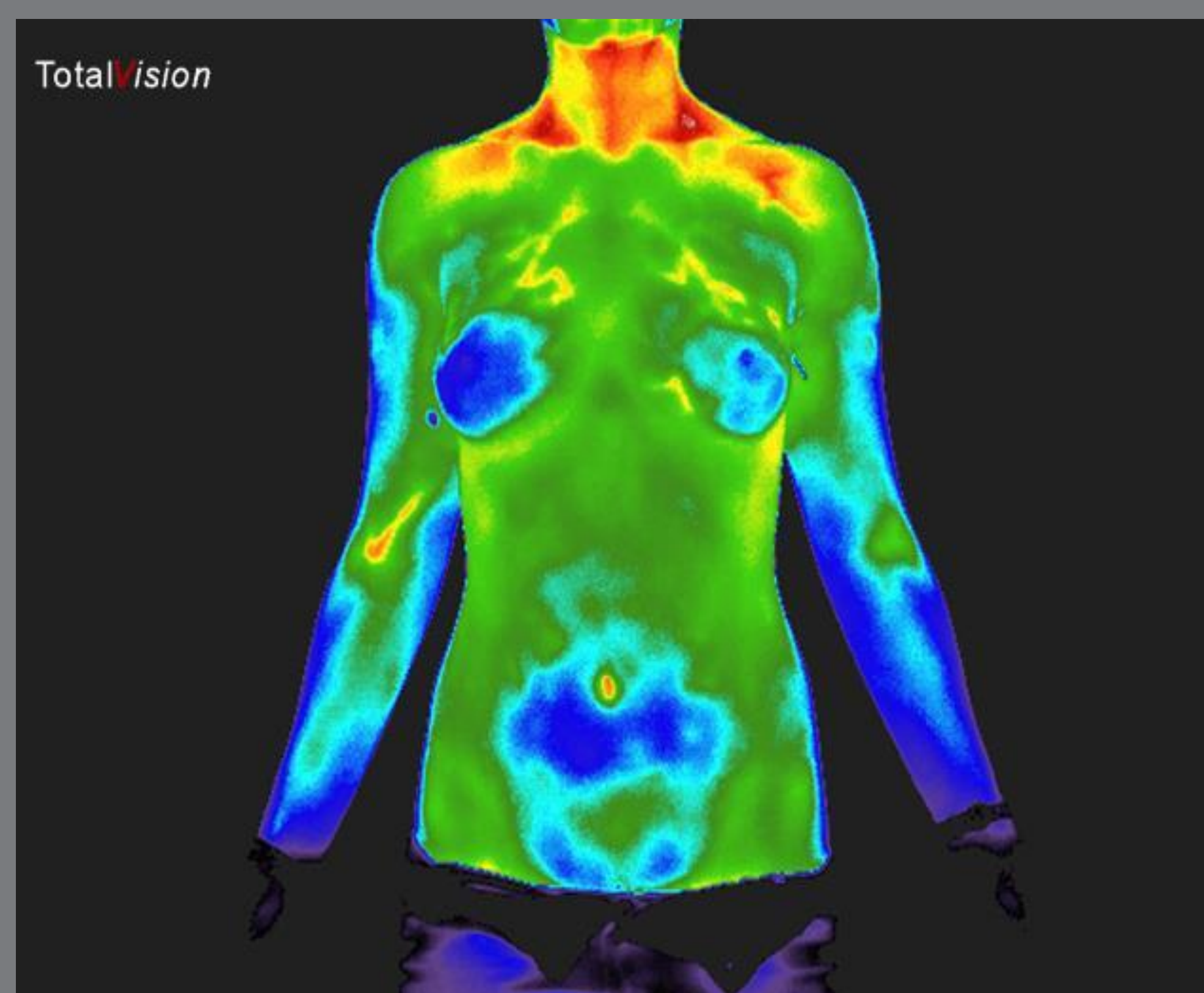
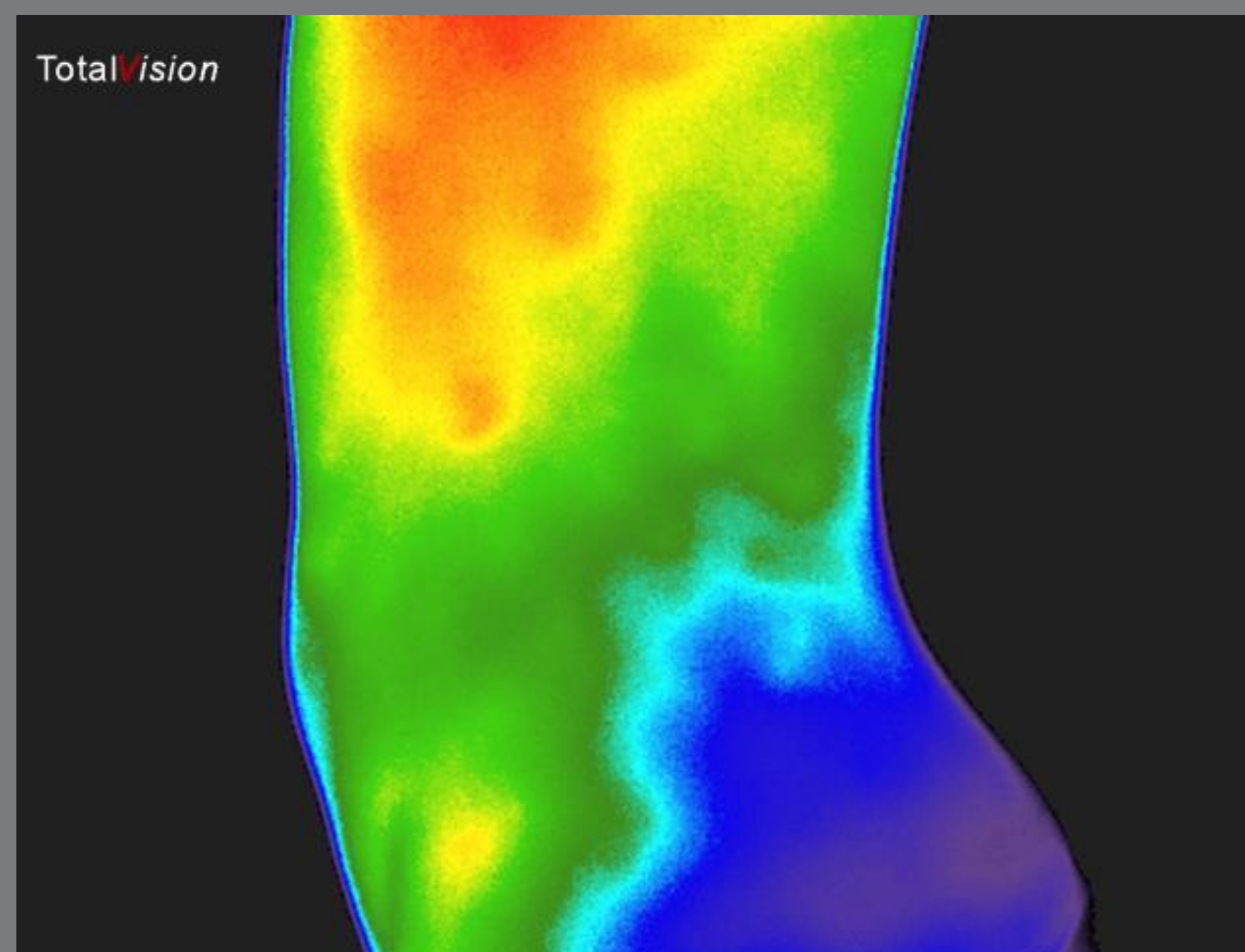
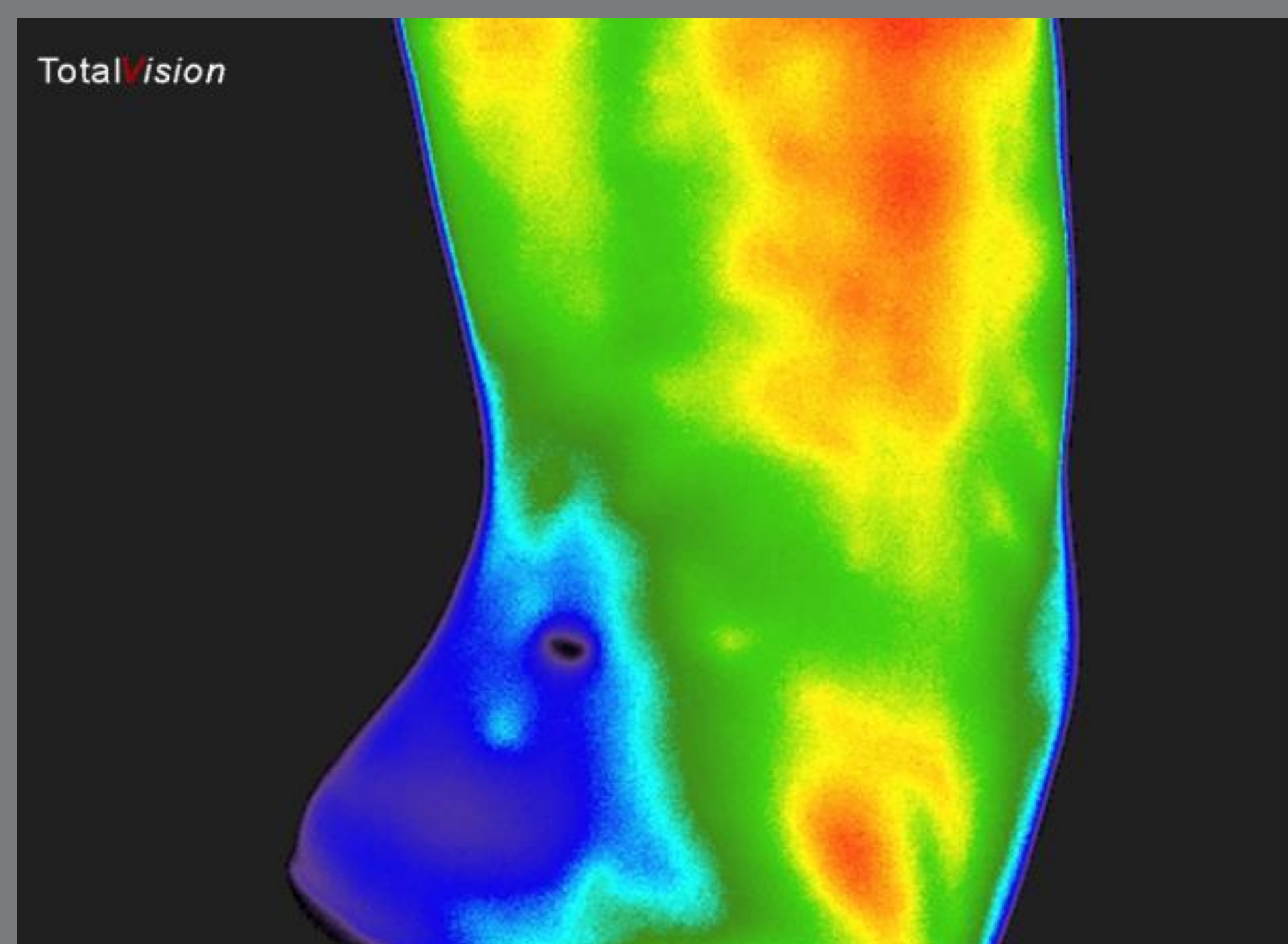
### Case M18-519

In March-2018, a 17-year old female came in for an initial abdomen study.

The patient's past medical history is significant for chronic abdominal pain. The pain is intense around her menstrual cycle. She reports other digestive complaints that are cyclical such as bloating and diarrhea just before her menstrual cycle. She has heavy periods that force her to stay home from school. Her symptoms are impacting her daily life.

She has seen numerous physicians with her family doctor suggesting birth control.

### Thermal Presentation



### Impressions and Discussion

The lateral views of the abdomen present with diffuse hyperthermia. We have seen this thermal presentation over and over with women who present with significant menstrual complaints. Over time we have clinically correlated this finding with endometriosis.

Also note the vascular activity in the left breast in the anterior trunk view (indicative of hormonal imbalance).

Hormonal imbalances left untreated can cause inflammation and a weakened immune system over time. Each of these conditions and symptoms is correlated with the onset of endometriosis.

### Treatment Protocol

Clinical diagnosis of endometriosis is invasive (laparoscopy). The patient did not want to embark on the journey of invasive procedures.

Under the care of a homeopath, the patient chose to implement a hormone balancing protocol. After one month, the patient reports noticeable improvement.

### Role of Thermography

Thermography is not a standalone diagnostic tool but it does have a unique role in identifying inflammatory markers which may be an indication of chronic disease.

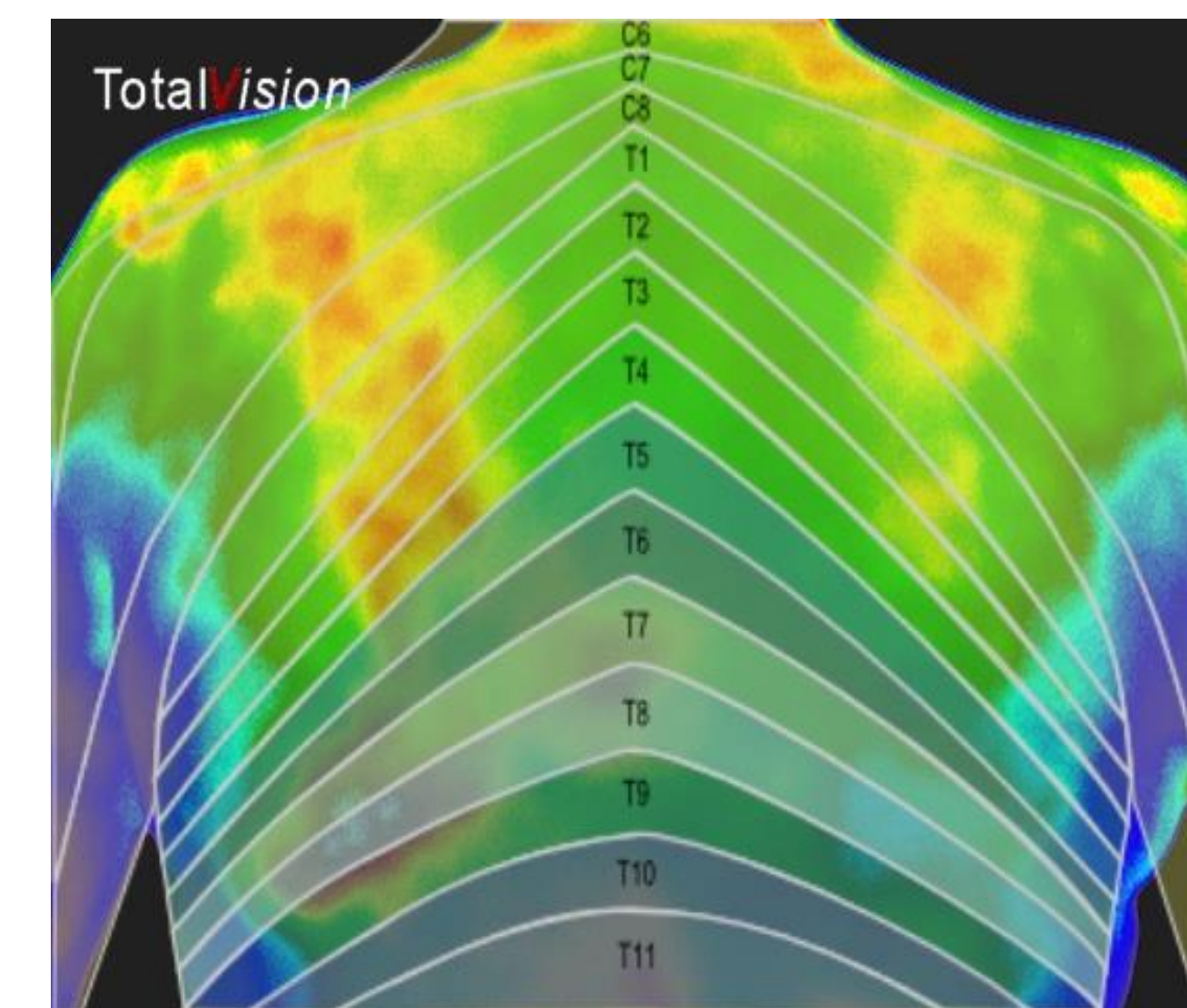
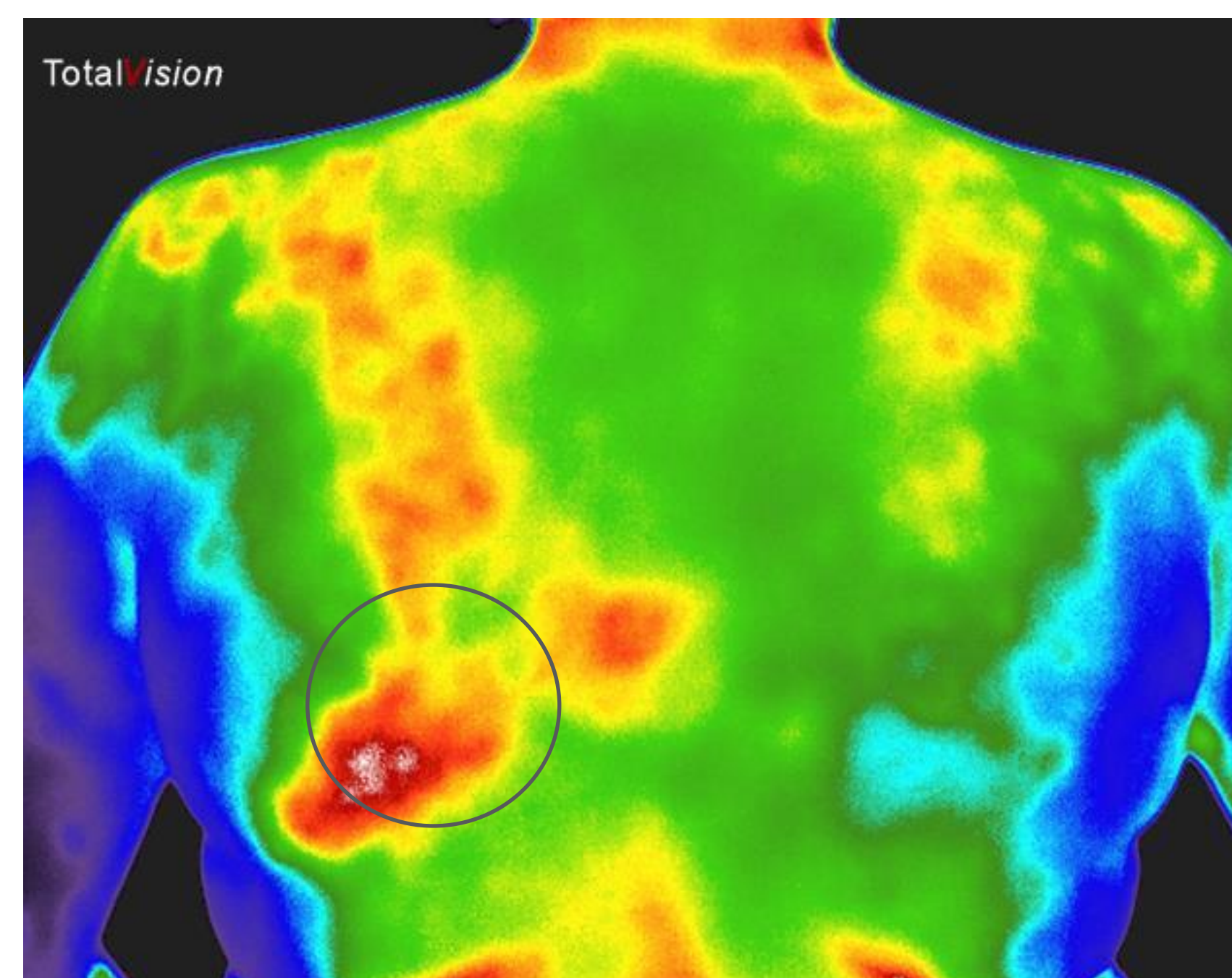
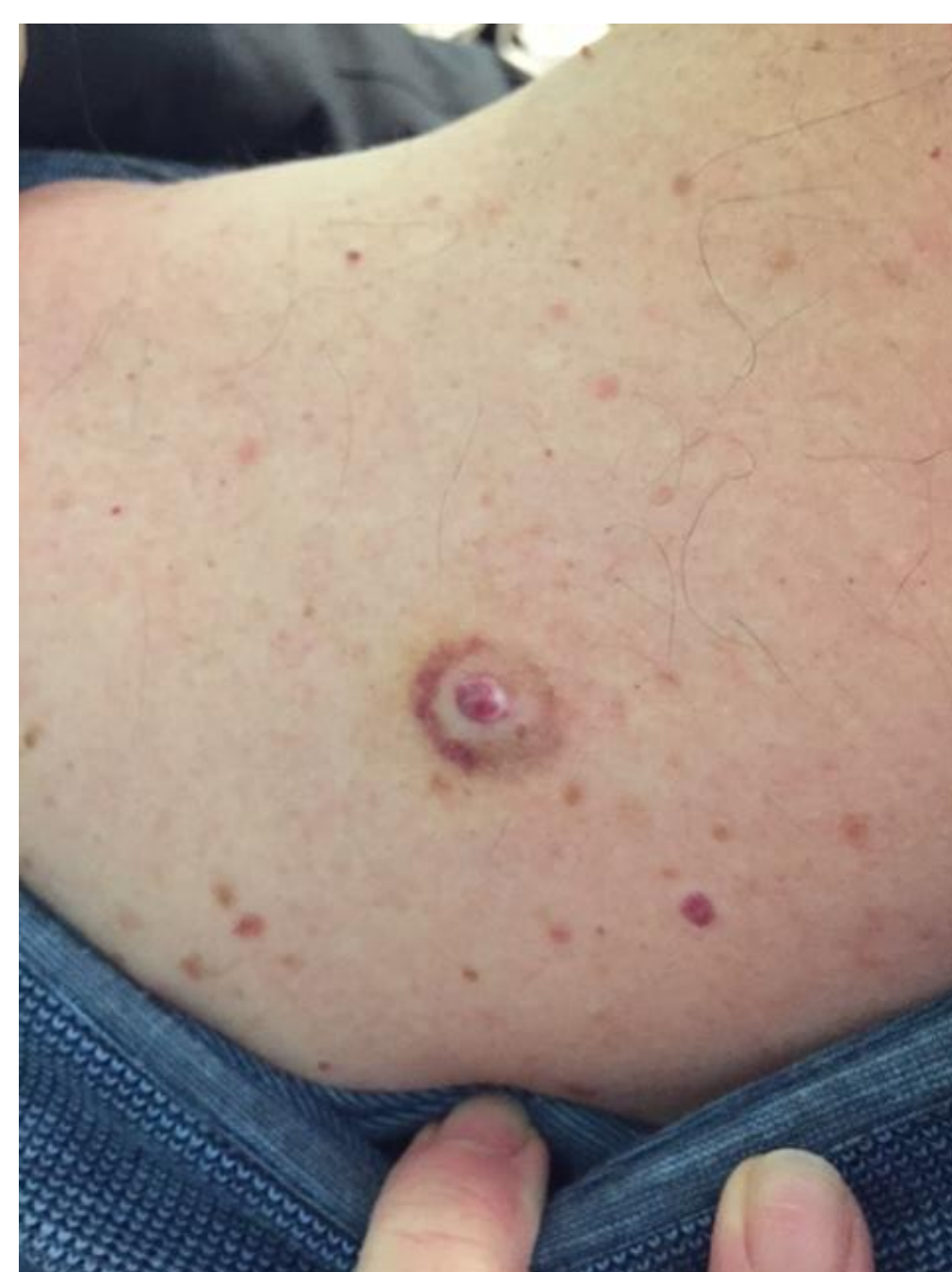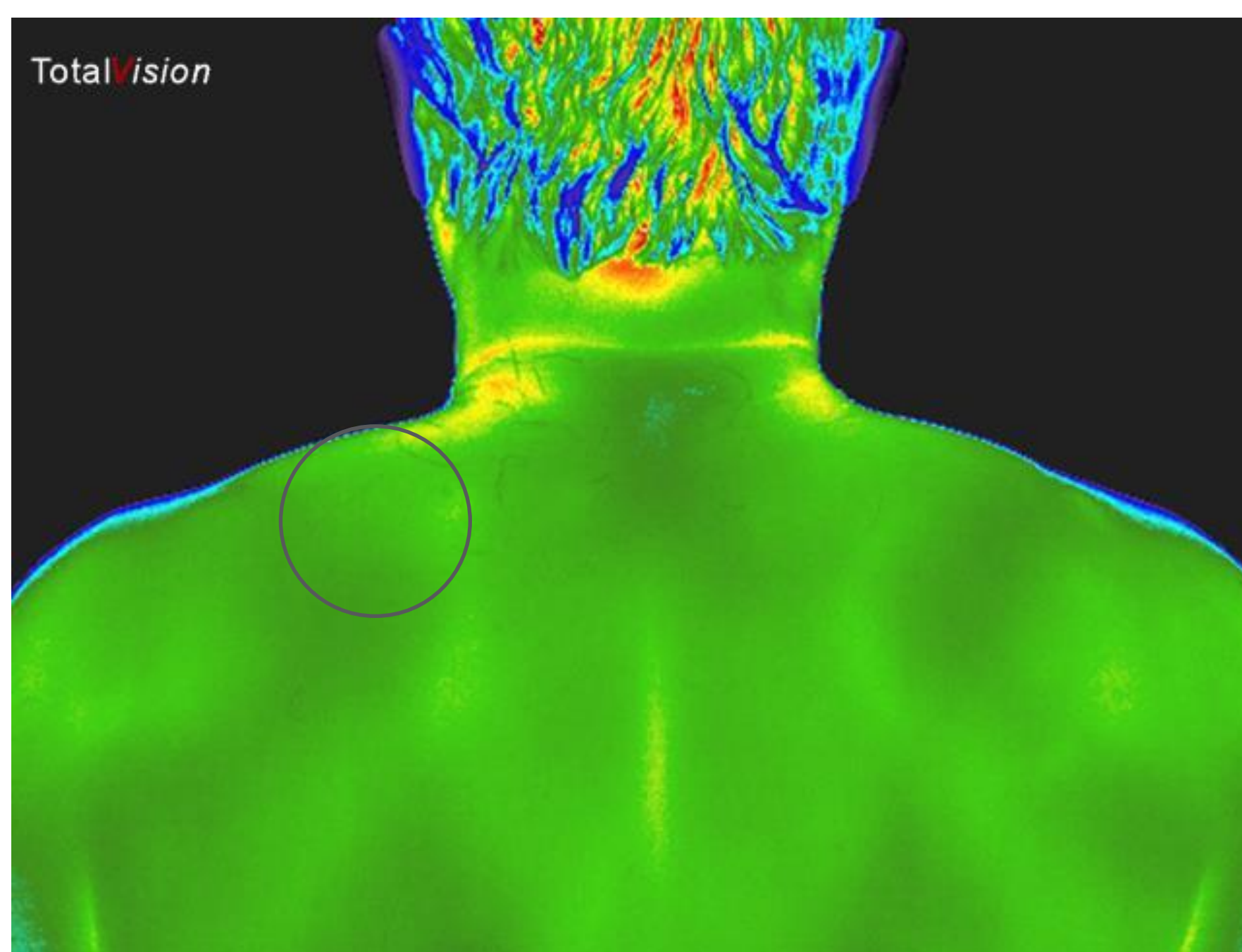


Lena Azevedo, CTT

Thermography Medical Clinic and D'Vine Living

### Introduction

Most skin lesions (or neoplasms) are benign but common diagnostic approaches are burdened by low diagnostic values and/or by their invasive nature. As inflammation is also present, the integration of thermography within the clinical setting is very useful in order to create a complete picture of most skin lesions – both as an assessment and as a post-treatment monitoring tool.



### Case M17-455

This back image presents with minimal thermal activity. This male patient complains of a large skin lesion over the upper left shoulder, marked with an eclipse. The accompanying digital image shows the same spot on the left shoulder.

The thermogram shows no asymmetry or increase in thermal activity in the area of the skin lesion. This skin lesion is most likely insignificant and is simply a cosmetic blemish.

Physical assessment by skin specialist and a biopsy confirmed that it is a benign skin lesion.

### Case M18-145

This thermogram presents with a large hyperthermic area with associated focal heat lateral and to the left of the spine along the T5 to the T8 dermatome region. Upon observation there was an obvious skin lesion, and the patient confirmed a type of cyst. The drainage pattern is marked with an eclipse.

Lateral and to the right of the spine along on the contralateral side there is a hypothermic pattern, indicative of a sympathetic response. The opposite side of the body may be trying to provide blood supply to the infected cyst to promote healing. Cysts, fatty lumps and various other types of skin lesions presenting along a certain dermatome region are indicative of an imbalance in the organ system associated with that dermatome region. Patient has not yet returned for a follow-up.

### Research Review

A recent review of the literature confirms that infrared thermography can play an important role in helping with early identification of skin conditions and with treatment evaluation and monitoring.

References:

1. Magalhaes, C., Vardasca, R. and Mendes, J. (2018). "Recent use of medical infrared thermography in skin neoplasms", Wiley Online Library (March-2018; <https://doi.org/10.1111/srt.12469>).
2. Cojocar, IM et al. (2015). "Thermal patterns in zoster", Journal of Medicine and Life (Vol. 8, Issue 3, July-September 2015, pp.346-349).
3. Netten, J. et al (2014). "Diagnostic Values for Skin Temperature Assessment to Detect Diabetes-Related Foot Complications", Diabetes Technology & Therapeutics (Vol. 16, Number 11, 2014, pp. 1-8).

### Role of Thermography

Thermography is not a standalone diagnostic tool but thermograms contain valuable information as the temperature distribution can be used to characterize physiological anomalies.