
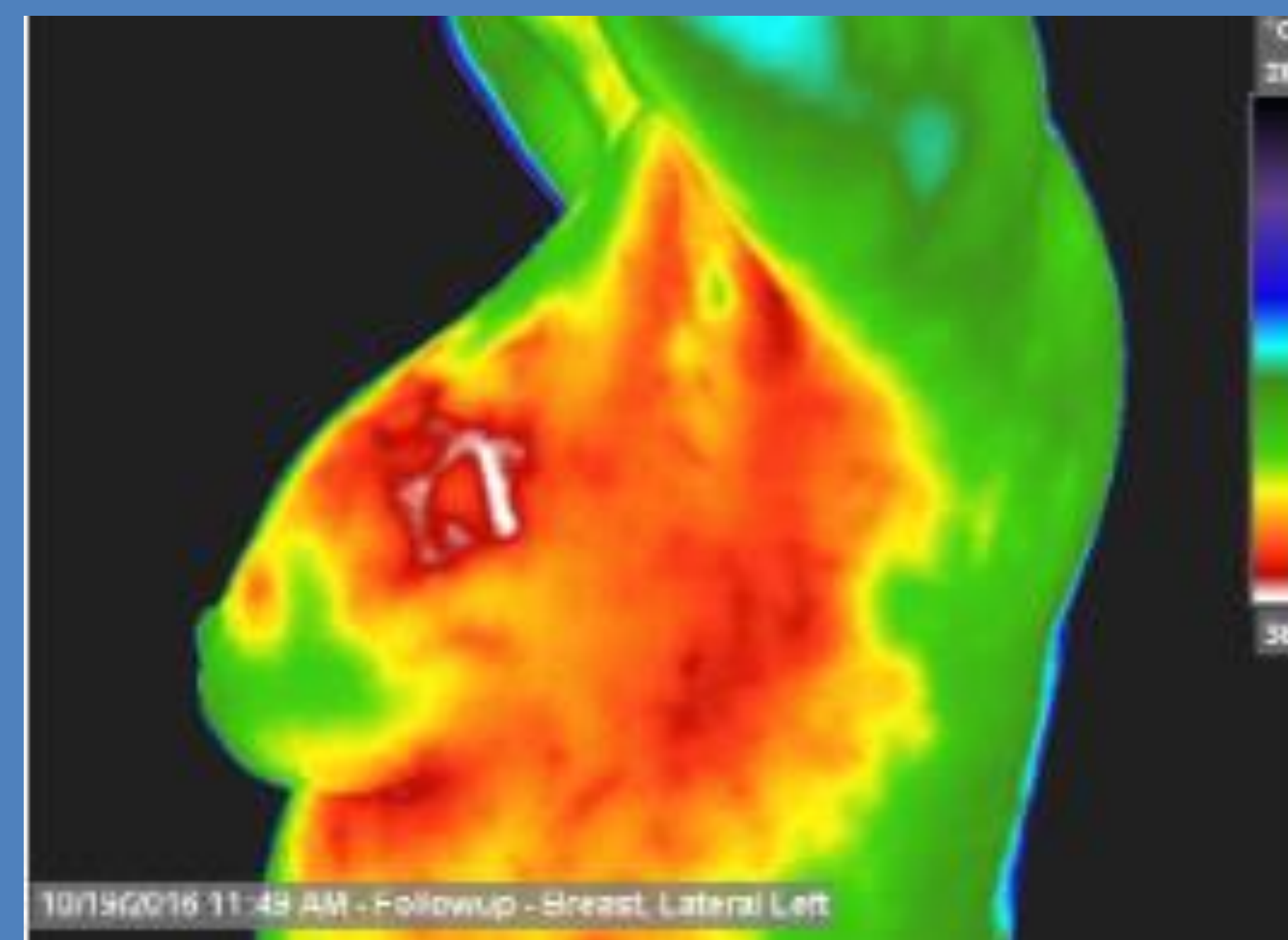
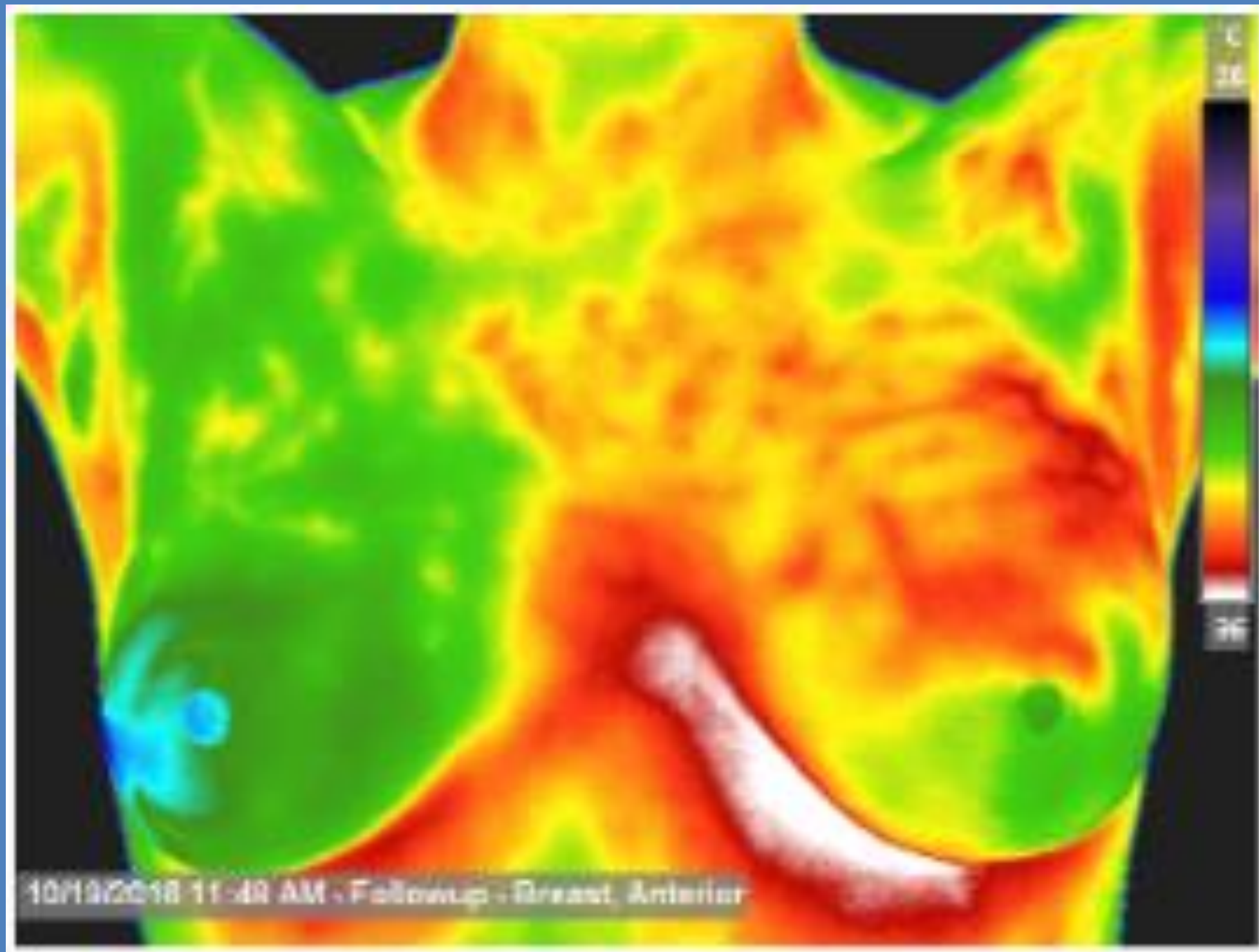


MONITORING TOOL

An Amazing Breast Transformation: Before & After

Kristin Burton CCT, CNHP
Central Florida Medical Thermography

BEFORE
10/19/2016



Introduction

Thermography cannot be used for breast cancer diagnosis but can alert a client to seek further clinical correlation. Utilizing the STAT program through Physicians Insight, Thermographers can help women with highly significant breast asymmetry get prompt evaluation

Patient: F – 48 yr old

The client presented with moderate pain in her left breast spreading across and down towards the nipple) with a lump at 2 o'clock. She had cysts before and was not particularly worried. She did not want to have a mammogram. She also had lower left back pain.

Findings

Significant thermal asymmetry was noticed immediately by the Thermographer and a STAT Interpretation was suggested. Interpretation reported a highly significant vascular pattern in the upper outer left breast about 2 o'clock, including a vascular loop pattern. Further testing revealed stage 4 breast cancer with metastasis to the spine.

March Follow Up

The client, decided on regimen of natural supplementation and a few radiation treatments to the spine to relieve pain. She was told in March that a PET scan revealed no more cancerous cells. She is currently cancer free.

AFTER
03/08/2017

